

NG:YAG LASER HYALOIDOTOMY FOR PREMACULAR HEMORRHAGE IN BOTH EYES IN A PATIENT WITH ACUTE MYELOBLASTIC LEUKEMIA

Malov IA^{1✉}, Strenev NV¹, Takhchidi KhP²

¹ Eye Microsurgery Ekaterinburg Center, Ekaterinburg, Russia

² Pirogov Russian National Research Medical University, Moscow, Russia

Premacular hemorrhage occurs in various disorders and causes sudden unilateral or bilateral visual impairment. One of the well-established techniques to treat this condition is Ng:YAG laser hyaloidotomy. Below we report a case of premacular hemorrhage in the right and left eyes of a 23-year old patient with acute myeloblastic leukemia. Ng:YAG laser hyaloidotomy was successfully performed on both patient's eyes at different puncture sites.

Keywords: premacular hemorrhage, YAG laser, posterior hyaloid membrane, acute myeloblastic leukemia

✉ **Correspondence should be addressed:** Igor Malov
ul. Akademika Bardina 4a, Ekaterinburg, Russia, 620149; malov64@gmail.com

Received: 10.04.2017 **Accepted:** 24.04.2017

ИАГ-ЛАЗЕРНАЯ ПУНКЦИЯ ПРИ ПРЕМАКУЛЯРНОМ КРОВОИЗЛИЯНИИ НА ОБОИХ ГЛАЗАХ У ПАЦИЕНТА С ОСТРЫМ МИЕЛОБЛАСТНЫМ ЛЕЙКОЗОМ

И. А. Малов^{1✉}, Н. В. Стренев¹, Х. П. Тахчиди²

¹ Екатеринбургский центр МНТК «Микрохирургия глаза», Екатеринбург

² Российский национальный исследовательский медицинский университет имени Н. И. Пирогова, Москва

Премакулярные кровоизлияния могут возникать по различным причинам и вызывают внезапное одно- или двустороннее снижение зрения. Одним из признанных вариантов лечения является ИАГ-лазерная пункция задней гиалоидной мембраны в зоне кровоизлияния. Авторы представляют случай успешной ИАГ-лазерной пункции премакулярных кровоизлияний на обоих глазах с различной локализацией точки пунктирования у 23-летнего пациента с острым миелобластным лейкозом.

Ключевые слова: премакулярное кровоизлияние, ИАГ-лазер, задняя гиалоидная мембрана, острый миелобластный лейкоз

✉ **Для корреспонденции:** Малов Игорь Александрович
ул. Академика Бардина, д. 4а, г. Екатеринбург, 620149; malov64@gmail.com

Статья получена: 10.04.2017 **Статья принята к печати:** 24.04.2017

Premacular hemorrhages (PMHs) lead to sudden and profound vision loss. They are caused by retinal vascular disorders (diabetic retinopathy or vein occlusion), age-related macular degeneration, Valsalva retinopathy, macroaneurysms, etc. [1–6]. Up to 49 % of patients with leukemia suffer from hemorrhages in the ocular fundus, of them 6 % have PMHs [7]. In most cases these lesions resolve spontaneously within a few weeks or months, depending on the size. But for socially active patients or those with hemorrhages in both eyes or in their only healthy eye recovery should be expedited. Besides, vision restoration has a positive psychological impact on patients with severe comorbidities. Of all known treatment approaches, including pneumatic displacement therapy with tissue plasminogen activator [8, 9], vitrectomy [10], and Ng:YAG laser hyaloidotomy [11–14], the latter is the safest and the most accessible.

Below we describe a case of a 23-year old patient with acute myeloblastic leukemia with PMHs in both eyes resulting in profound visual impairment. Ng:YAG laser posterior hyaloidotomy was performed on both eyes of the patient, with a few minute break between the procedures. This case presents a particular interest, because due to the location of

the hemorrhage inferior margin in the fovea of the patient's left eye, it was decided to make the opening above the fovea to avoid retinal damage. For the right eye the puncture site was conventionally chosen at the inferior margin of the lesion. Post-treatment follow-up revealed that hemorrhages resorbed differently in the right and left eyes.

Case description

A 23-year old patient with acute myeloblastic leukemia undergoing polychemotherapy presented with profound vision loss following premacular hemorrhages in both eyes six weeks earlier. Upon admission best corrected visual acuity (Vis) was 0.1 for the right eye (OD) and 0.05 for the left eye (OS); intraocular pressure (IOP) was as follows: IOP OD = 20 mmHg, IOP OS = 20 mmHg. In both eyes preretinal hemorrhages were observed in the posterior pole of the ocular fundus, extending to the fovea. The size of the lesion area in the macula was about 5 diameters of the optic disc in the right eye and 3 diameters of the disc in the left eye. We performed Ng:YAG

laser posterior hyaloidotomy above the lesion area in both eyes using the VISULAS YAG III platform (Carl Zeiss Meditec AG, Germany) with a wavelength of 1064 nm and spot diameter of 10 μ m in two single bursts at E = 2 mJ in each eye with a few minute break between the procedures. The central fovea lies 500 μ m below the horizontal line bisecting the optic disc [15]. In our experience, the opening in the hyaloid membrane should be made no closer than 1000 μ m to the central fovea to avoid damage to the latter. Therefore, it was decided to perform hyaloidotomy of the right eye at the inferior margin of the lesion, 2500 μ m below the horizontal line (Fig. 1, A). But as the inferior margin of the hemorrhage in the left eye was in the foveal area, we decided to make an opening 1000 μ m above the fovea, or 500 μ m above the horizontal line (Fig. 1, B).

A week after hyaloidotomy best corrected Vis OD was 0.7, best corrected Vis OS was 0.08, IOP OD was 19 mmHg, IOP OS was 19 mmHg. Areas of residual hemorrhage were observed in the macula of both eyes (Fig. 2, A). Optical coherence tomography (OCT) performed with the Avanti RTVue 100 scanner (Optovue, USA) revealed highly reflective opacities in the vitreous and an opening in the partially detached posterior hyaloid membrane in the right eye AND highly reflective opacities above the fovea (areas of residual hemorrhage) and an opening in the partially detached posterior hyaloid membrane in the left eye (Fig. 3, A). Results 5 weeks after hyaloidotomy: best corrected Vis OD = 0.7, best corrected Vis OS = 0.1, IOP OD = 18 mmHg, IOP OS = 16 mmHg; complete hemorrhage diffusion in the right eye's macula, small areas of residual hemorrhage in the left eye's fovea (Fig. 2, B). Results 14 weeks after hyaloidotomy: corrected Vis OD = 1.0, corrected Vis OS = 0.6, IOP OD = 18 mmHg, IOP OS = 16 mmHg, complete resorption of the hemorrhage in the right eye's macula, small areas of residual hemorrhage in the left eye's macula (Fig. 2, C). OCT revealed almost complete resorption of highly reflective opacities above the fovea in both eyes (Fig. 3, B). No changes in visual acuity were seen in further follow-up examinations.

Case discussion

Ng:YAG laser posterior hyaloidotomy is an effective and safe technique for treating premacular hemorrhages. Traditionally, it is performed at the inferior margin of the lesion for rapid blood drainage, which is assisted by gravity and oscillations of the detached posterior hyaloid membrane above the lesion that are in turn triggered by the oscillations of the vitreous accompanying normal eye movements. The opening must be far enough from the fovea to avoid damage to the latter. In the described clinical case indications for hyaloidotomy of the right eye were unquestionable. It was risky, however, to perform the

procedure at the inferior margin of the lesion in the left eye. A decision was made to make an opening above the fovea. Obviously, considering such location of the opening, gravity will not facilitate blood drainage from the lesion area below the puncture site. But we assumed that blood drainage could be assisted by small oscillations of the detached posterior hyaloid membrane above the lesion that are a result of oscillations of the vitreous that accompany eye movements. The follow-up examinations confirmed our assumptions. But as we had expected, resorption of the hemorrhage in the left eye took longer (1 month longer) than in the right eye, in spite of a smaller lesion size.

CONCLUSIONS

Ng:YAG laser posterior hyaloidotomy performed above the lesion area is an effective and safe technique for treating premacular hemorrhages in patients with acute myeloblastic leukemia undergoing chemotherapy.

The case presented above demonstrates the possibility of treating premacular hemorrhages extending to the fovea with Ng:YAG laser puncture. The opening should be made above the fovea, unlike standard openings usually made at the inferior margin of the lesion. However, such location of the puncture site will result in slower hemorrhage resorption.

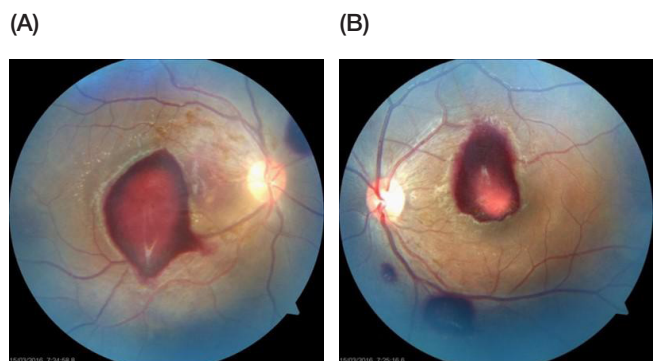


Fig. 1. Fundus photos of the right (A) and left (B) eyes of the patient upon admission to the clinic

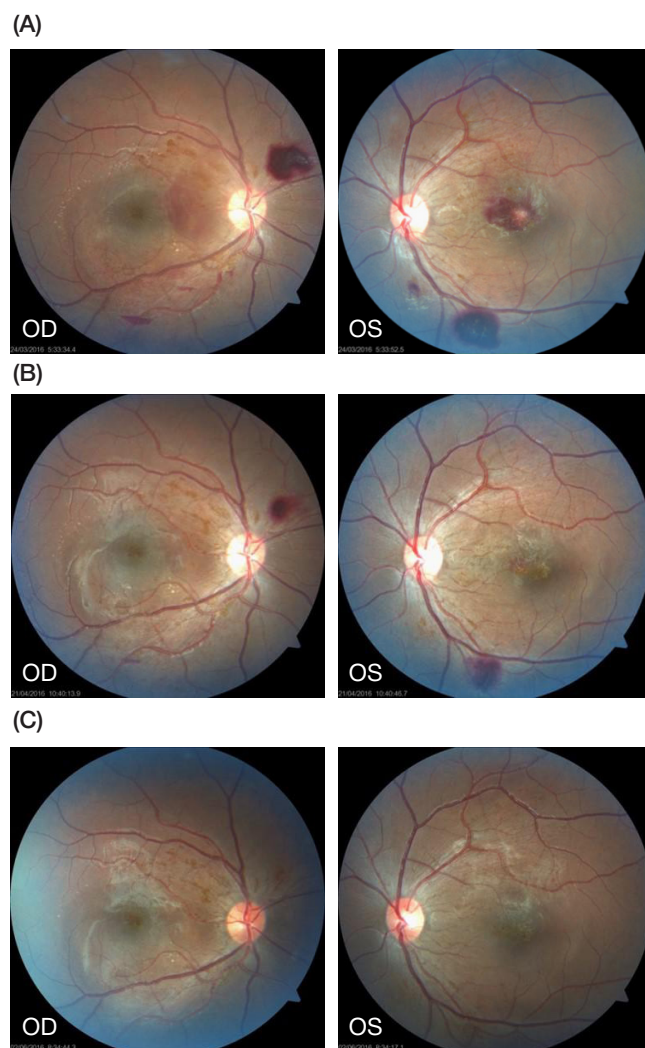


Fig. 2. Fundus photos of the right (OD) and left (OS) eyes of the patient (A) 1 week, (B) 5 weeks and (C) 14 weeks after Ng:YAG laser posterior hyaloidotomy

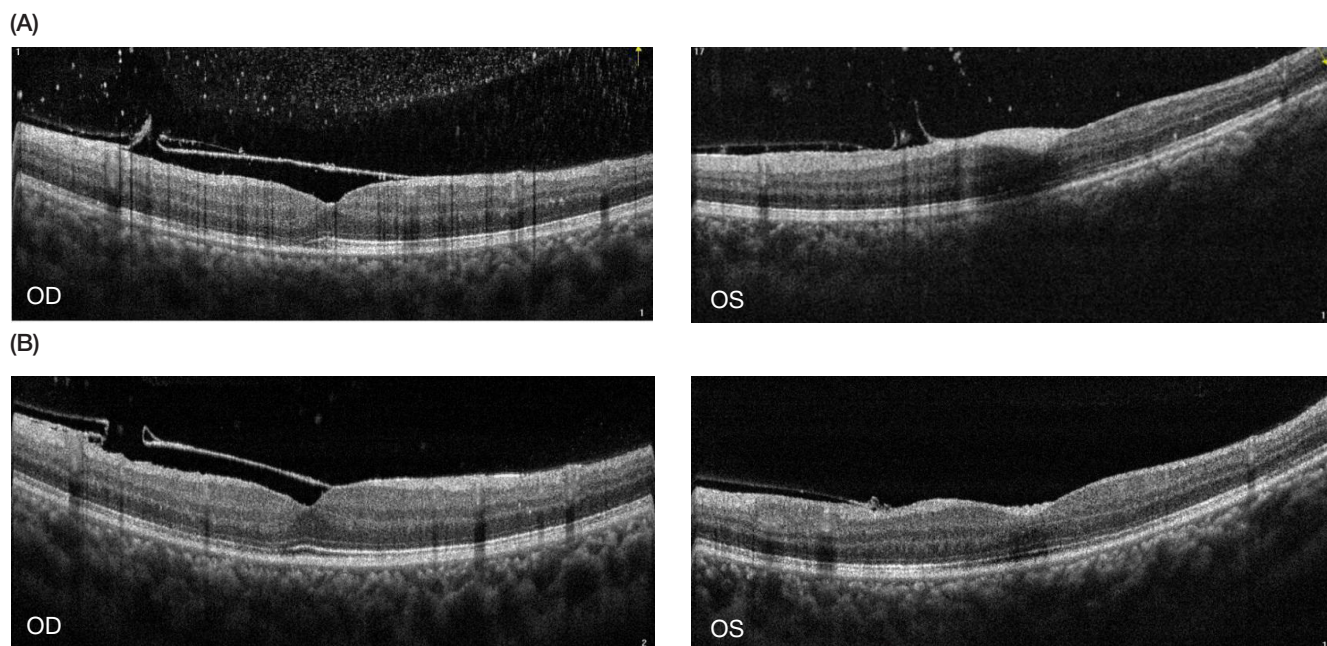


Fig. 3. Optical coherence tomography of the macula of the right (OD) and left (OS) eyes of the patient (A) 1 week and (B) 14 weeks after Nd:YAG laser hyaloidotomy

References

- Punjabi OS, Flynn HW Jr, Knighton RW, Gregori G, Couvillion SS, Lalwani GL, et al. Spectral domain optical coherence tomography for proliferative diabetic retinopathy with subhyaloid hemorrhage. *Ophthalmic Surg Lasers Imaging*. 2008 Nov-Dec; 39 (6): 494–6.
- Buliga S, Toma C, Taina A, Beraru V, Benone C. [Diabetic retrolialoidian hemorrhage — invasive minimal treatment]. *Oftalmologia*. 2011; 55 (4): 82–5. Romanian.
- Kashani S, Aslam SA, Bessant D. Valsalva retinopathy presenting with subhyaloid haemorrhage. *Emerg Med J*. 2009 Jan; 26 (1): 74.
- Gedik S, Gür S, Yilmaz G, Akova YA. Retinal arterial macroaneurysm rupture following fundus fluorescein angiography and treatment with Nd:YAG laser membranectomy. *Ophthalmic Surg Lasers Imaging*. 2007 Mar-Apr; 38 (2): 154–6.
- Völcker D, Junker B, Hansen LL. [Spontaneous macula hemorrhage. Subhyaloid/sub-inner limiting membrane (ILM)]. *Ophthalmologie*. 2012 Jul; 109 (7): 702–6. German.
- Mansour AM, Lee JW, Yahng SA, Kim KS, Shahin M, Hamerschlag N, et al. Ocular manifestations of idiopathic aplastic anemia: retrospective study and literature review. *Clin Ophthalmol*. 2014 Apr 17; 8: 777–87.
- Reddy SC, Jackson N. Retinopathy in acute leukaemia at initial diagnosis: correlation of fundus lesions and haematological parameters. *Acta Ophthalmol Scand*. 2004 Feb; 82 (1): 81–5.
- Conway MD, Peyman GA, Recasens M. Intravitreal tPA and SF6 promote clearing of premacular subhyaloid hemorrhages in shaken and battered baby syndrome. *Ophthalmic Surg Lasers*. 1999 Jun; 30 (6): 435–41.
- Koh HJ, Kim SH, Lee SC, Kwon OW. Treatment of subhyaloid haemorrhage with intravitreal tissue plasminogen activator and C3F8 gas injection. *Br J Ophthalmol*. 2000 Nov; 84 (11): 1329–30.
- Ramsay RC, Knobloch WH, Cantrill HL. Timing of vitrectomy for active proliferative diabetic retinopathy. *Ophthalmology*. 1986 Mar; 93 (3): 283–9.
- Shchuko AG, Starunov EV, Malyshev VV. ND:YAG-lazernaya gialoido/retinotomiya v lechenii makulyarnykh krovoizliyanii. In: *Sbornik tezisov dokladov II Vserossiiskogo seminara «Makula-2006»*. Rostov-on-Don: InterYuNA; 2006. p. 398–400. Russian.
- Magaramov DA. Effektivnost' lazernykh metodov lecheniya patsientov pri obshirnykh krovoizliyaniiakh v tsentral'noi zone setchatki. In: Takhchidi KhP, Malyugin BE, Lyskin PV, Klimova TL, Pronina II, editors. *Sovremennye tekhnologii lecheniya vitreoretinal'noi patologii-2007: sbornik nauchnykh statei po materialam nauchno-prakticheskoi konferentsii*; 2007 Mar 23; Moscow, Russia. Moscow: Eye Microsurgery Ekaterinburg Center; 2007. p. 151–4. Russian.
- Pogodina YeG, Ilyukhin DA. [Two clinical cases with application of YAG-laser hyaloidotomy methods]. *Vestnik of the Orenburg State University*. 2012; 148 (12): 155–7. Russian.
- Kanyukov VN, Pogodina EG, Kanyukova YuV, Ilyukhin DA. Opyt primeneniya gialoido- i retinopunktury pri makulyarnykh krovoizliyaniiakh razlichnoi etiologii. *Sovremennye tekhnologii v oftal'mologii*. 2014; (1): 55–6. Russian.
- Blanks JC. Morphology and Topography of the Retina. In: Ryan SJ, editor. *Retina*. 3rd ed. St. Lois: Mosby; 2001. vol. 1. p. 32–53.

Литература

- Punjabi OS, Flynn HW Jr, Knighton RW, Gregori G, Couvillion SS, Lalwani GL, et al. Spectral domain optical coherence tomography for proliferative diabetic retinopathy with subhyaloid hemorrhage. *Ophthalmic Surg Lasers Imaging*. 2008 Nov-Dec; 39 (6): 494–6.
- Buliga S, Toma C, Taina A, Beraru V, Benone C. [Diabetic retrolialoidian hemorrhage — invasive minimal treatment]. *Oftalmologia*. 2011; 55 (4): 82–5. Romanian.
- Kashani S, Aslam SA, Bessant D. Valsalva retinopathy presenting with subhyaloid haemorrhage. *Emerg Med J*. 2009 Jan; 26 (1): 74.
- Gedik S, Gür S, Yilmaz G, Akova YA. Retinal arterial macroaneurysm rupture following fundus fluorescein angiography

- and treatment with Nd:YAG laser membranectomy. *Ophthalmic Surg Lasers Imaging*. 2007 Mar-Apr; 38 (2): 154–6.
5. Völcker D, Junker B, Hansen LL. [Spontaneous macula hemorrhage. Subhyaloid/sub-inner limiting membrane (ILM)]. *Ophthalmologe*. 2012 Jul; 109 (7): 702–6. German.
 6. Mansour AM, Lee JW, Yahng SA, Kim KS, Shahin M, Hamerschlak N, et al. Ocular manifestations of idiopathic aplastic anemia: retrospective study and literature review. *Clin Ophthalmol*. 2014 Apr 17; 8: 777–87.
 7. Reddy SC, Jackson N. Retinopathy in acute leukaemia at initial diagnosis: correlation of fundus lesions and haematological parameters. *Acta Ophthalmol Scand*. 2004 Feb; 82 (1): 81–5.
 8. Conway MD, Peyman GA, Recasens M. Intravitreal tPA and SF6 promote clearing of premacular subhyaloid hemorrhages in shaken and battered baby syndrome. *Ophthalmic Surg Lasers*. 1999 Jun; 30 (6): 435–41.
 9. Koh HJ, Kim SH, Lee SC, Kwon OW. Treatment of subhyaloid haemorrhage with intravitreal tissue plasminogen activator and C3F8 gas injection. *Br J Ophthalmol*. 2000 Nov; 84 (11): 1329–30.
 10. Ramsay RC, Knobloch WH, Cantrill HL. Timing of vitrectomy for active proliferative diabetic retinopathy. *Ophthalmology*. 1986 Mar; 93 (3): 283–9.
 11. Щуко А. Г., Старунов Э. В., Малышев В. В. ND:YAG-лазерная гиалоидо/ретиномия в лечении макулярных кровоизлияний. В кн.: Сборник тезисов докладов II Всероссийского семинара «Макула-2006». Ростов-на-Дону: ИнтерЮНА; 2006. с. 398–400.
 12. Магарамов Д. А. Эффективность лазерных методов лечения пациентов при обширных кровоизлияниях в центральной зоне сетчатки. В кн.: Тахчиди Х. П., Малюгин Б. Э., Лыскин П. В., Климова Т. Л., Пронина И. И., редакторы. Современные технологии лечения витреоретинальной патологии-2007: сборник научных статей по материалам научно-практической конференции; 23 марта 2007 г.; Москва, Россия. М.: МНТК «Микрохирургия глаза»; 2007. с. 151–4.
 13. Погодина Е. Г., Илюхин Д. А. Два клинических случая с применением методики ИАГ-лазерной гиалоидотомии. *Вестн. ОГУ*. 2012; 148 (12): 155–7.
 14. Канюков В. Н., Погодина Е. Г., Канюкова Ю. В., Илюхин Д. А. Опыт применения гиалоидо- и ретинопунктуры при макулярных кровоизлияниях различной этиологии. *Современные технологии в офтальмологии*. 2014; (1): 55–6.
 15. Blanks JC. Morphology and Topography of the Retina. In: Ryan SJ, editor. *Retina*. 3rd ed. St. Lois: Mosby; 2001. vol. 1. p. 32–53.