

FORMATION OF ARTERIOVENOUS FISTULA FOLLOWING SURGICAL RESECTION OF VESTIBULAR SCHWANNOMA

Reutov AA¹✉, Aronov MS², Kushel YuV³

¹ Central Clinical Hospital of the Presidential Administration of the Russian Federation, Moscow

² Burnasyan Federal Medical Biophysical Center, Moscow

³ Burdenko Neurosurgical Institute, Moscow

Iatrogenic arteriovenous fistulas make up only 0.22% of all fistulas. This article reports a postoperative arteriovenous fistula in a female patient who initially presented with a vestibular schwannoma and was operated using the retrosigmoid approach. Undesired clinical symptoms developed after the patient had been discharged home, and included pulsatile tinnitus, which intensified when the patient tilted or turned her head. The diagnosis was established based on cerebral angiography findings during the second hospital stay. This case report describes complications of retrosigmoid craniotomy, clinical manifestations of the arteriovenous fistula and successful fistula embolization.

Keywords: vestibular schwannoma, retrosigmoid approach, arteriovenous fistula

✉ **Correspondence should be addressed:** Andrey A. Reutov
ul. Marshala Timoshenko 15, Moscow, 121359; reutov@centerneuro.ru

Received: 19.01.2018 **Accepted:** 20.02.2018

DOI: 10.24075/brsmu.2018.034

АРТЕРИОВЕНОЗНАЯ ФИСТУЛА ПОСЛЕ УДАЛЕНИЯ ВЕСТИБУЛЯРНОЙ ШВАННОМЫ

А. А. Реутов¹✉, М. С. Аронов², Ю. В. Кушель³

¹ Центральная клиническая больница с поликлиникой, Управление делами Президента Российской Федерации, Москва

² Федеральный медицинский биофизический центр имени А. И. Бурназяна, Москва

³ Национальный медицинский исследовательский центр нейрохирургии имени Н. Н. Бурденко, Москва

Формирование артериовенозной фистулы в результате хирургических манипуляций составляет всего 0,22% всех случаев ее возникновения. В работе описано формирование артериовенозной фистулы у пациентки с вестибулярной шванномой, удаленной путем ретросигмовидного доступа. Клинические проявления фистулы в виде пульсирующего шума, усиливающегося при поворотах и наклонах головы, появились отсрочено после выписки. Диагноз был подтвержден с помощью прямой церебральной ангиографии во время повторной госпитализации. Описываются возможные осложнения хирургического лечения, клинические проявления и результаты успешного лечения артериовенозной фистулы путем эндоваскулярного разобщения.

Ключевые слова: вестибулярная шваннома, ретросигмовидный доступ, артериовенозная фистула

✉ **Для корреспонденции:** Андрей Александрович Реутов
ул. Маршала Тимошенко, д. 15, Москва, 121359; reutov@centerneuro.ru

Статья получена: 19.01.2018 **Статья принята к печати:** 20.02.2018

DOI: 10.24075/vrgmu.2018.034

Vestibular schwannomas, also known as acoustic neuromas, are slow-growing benign tumors arising from Schwann cells in the vestibular portion of the vestibulocochlear nerve [1]. Advances in neuroimaging have considerably improved detection of these tumors, which reportedly occur in 0.6-1.9 individuals per 100, 000 population [2]. The choice of treatment is dictated by the patient's age, severity of their condition, neurological status, tumor size and features. Treatment options include microsurgery, stereotactic radiosurgery and radiotherapy [3]. The gold standard in the treatment of large vestibular schwannomas is microsurgical resection commonly performed using the translabyrinthine [4], middle cranial fossa [5] or retrosigmoid approaches [6]. The latter can be harnessed to remove vestibular schwannomas of any size [7]. However, the surgical intervention is associated with mortality and postoperative complications in 0.2% and 22% of patients, respectively [8]. The most common side effects of retrosigmoid craniotomy for vestibular schwannomas fall into 2 major arbitrary categories: neurological and surgical. Neurological complications are normally limited to cranial nerve damage.

The bulbar group of cranial nerves is often affected if the tumor extends caudally [9]. Damage to the facial nerve is seen in 25% of patients [10], while post-op trigeminal nerve dysfunction is observed in 4.7% of individuals [11]. Twelve percent of patients undergoing retrosigmoid craniotomy report aggravated gait unsteadiness associated with damage to the cerebellum or brain stem [1]. Cerebrospinal fluid leak and meningitis are the most common complications and occur in 15% [12] and 14% [13] of patients, respectively. Severe vascular disorders associated with retrosigmoid craniotomy, such as bleeding or ischemia, occur in 2.7% of patients [14].

Postoperative arteriovenous fistulas are a very rare complication of retrosigmoid craniotomy; their clinical manifestations are delayed [15]. The retrosigmoid approach to the skull base implies surgical manipulations in close proximity to the vertebral artery, posing a risk of injury to this blood vessel. Minor iatrogenic damage to the vertebral artery is sometimes overlooked during the surgery [16]. Although the artery lies outside the surgical field, it still can be accidentally injured due to the loss of anatomical landmarks or its own aberrant course.

For example, it can form a loop between the foramen magnum and C2 or travel outside the groove on the surface of the C1 posterior arch [17]. The risk of injury to the artery during the surgery involving exposure of the upper cervical spine is 4% to 8% [18].

Clinical case report

A female patient aged 39 presented to the neurosurgical unit complaining of right-sided hearing loss, facial numbness on the right side, imbalance, and unsteady gait. Contrast-enhanced MRI was suggestive of a right-sided Koos grade IV vestibular schwannoma sized 38.5 × 35 × 38 mm compressing the brain stem and the fourth ventricle (Fig. 1).

The tumor was surgically removed using the retrosigmoid approach; intraoperative neurophysiological monitoring was carried out throughout the surgery. During the surgery, soft tissue dissection caused profuse bleeding from the vertebral artery. The bleeding was stopped by tamponade and a single suture closing the small arterial wall defect under direct visual control. The vessel patency was completely preserved. The tumor was fully excised. Postoperative recovery was normal. The patient predictably developed House-Brackmann grade IV facial nerve palsy and weakness of the trigeminal nerve. She was discharged home on day 8 after the surgery; her condition

was satisfactory. However, the patient soon noticed pulsatile tinnitus, which intensified when she turned or tilted her head. No post-op complications or tumor remnants were visible on follow-up MRI (Fig. 2); MRA also detected no vascular abnormalities (Fig. 3). Considering the progressing symptoms, the patient was referred to the endovascular unit for further examination and treatment.

On admission to the endovascular unit, the patient complained of intensified pulsatile tinnitus and headaches. Cerebral angiography revealed an arteriovenous fistula connecting the right vertebral artery to the surrounding venous plexus. No vertebrobasilar opacification was observed distal to the fistula. Blood flow was equal in both right and left vertebral arteries. At the time of the examination, the fistula was only contrast-opacified anterogradely (Fig. 4). No opacification of the fistula was observed on the angiogram of the contralateral vertebral artery. Blood supply to the vertebrobasilar system, including the right posterior inferior cerebellar artery, came only from the left vertebral artery. Following the analysis of the obtained imaging data, endovascular repair was performed under general anesthesia. Briefly, a guiding catheter was introduced into the proximal right vertebral artery. Under the guidance of X-ray road map fluoroscopy, the Echelon-10 microcatheter (Medtronic, USA) was advanced to the fistula using the Silverspeed micro guidewire (Medtronic, USA). To

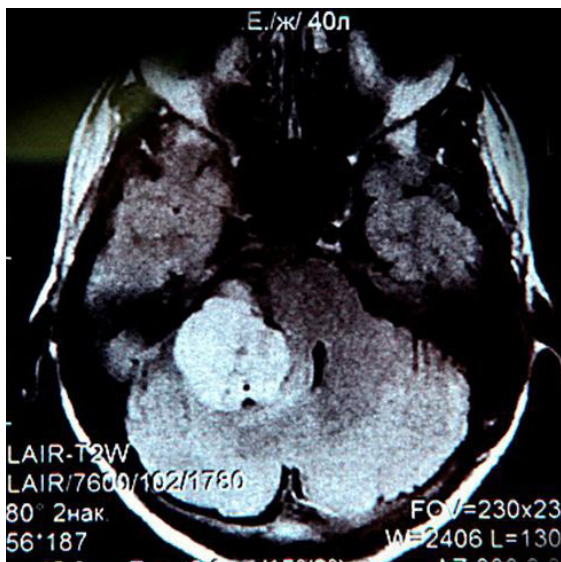


Fig. 1. The T1-weighted contrast-enhanced MR image taken before the surgery shows a typical right-sided vestibular schwannoma

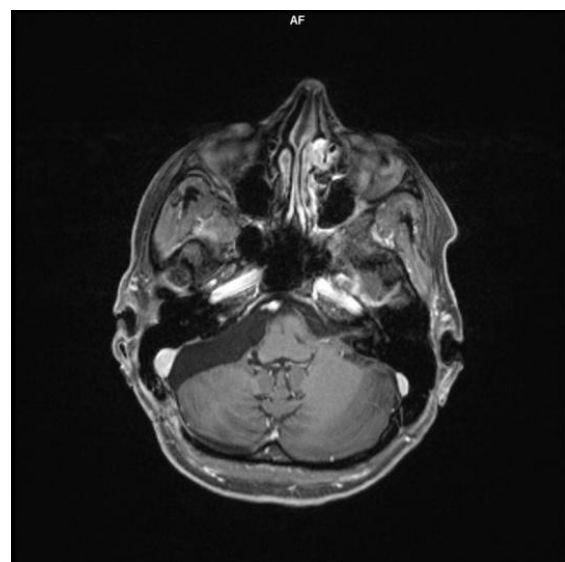


Fig. 2. The T1-weighted contrast-enhanced MR image taken after the surgery shows no tumor remnants or postoperative complications

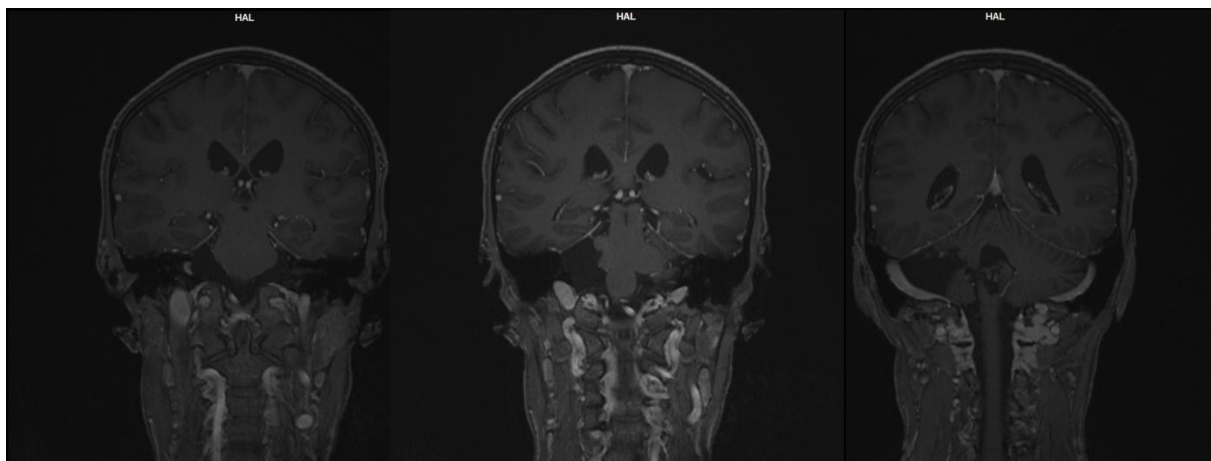


Fig. 3. Postoperative magnetic resonance angiography images showing no vascular damage

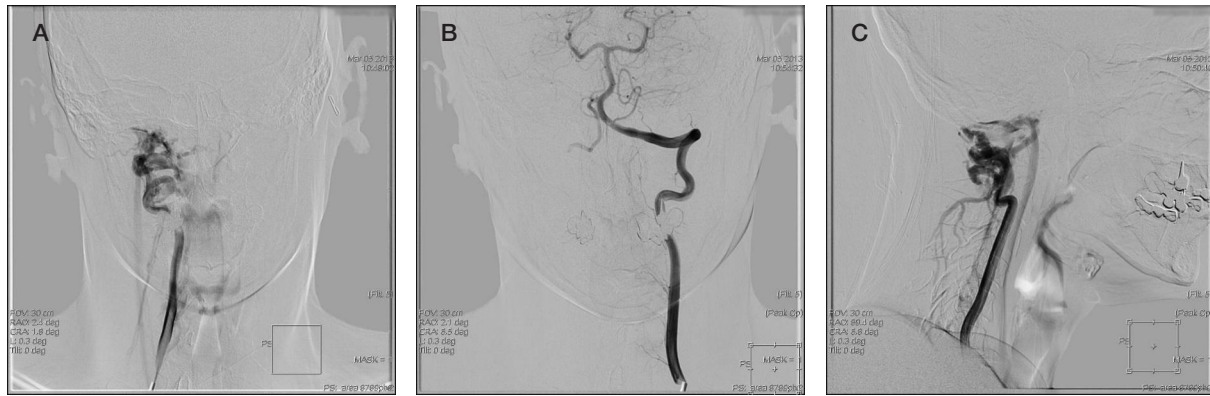


Fig. 4. The initial angiogram of the right vertebral artery (A), left vertebral artery, frontal view (B), and right vertebral artery, lateral view (C)

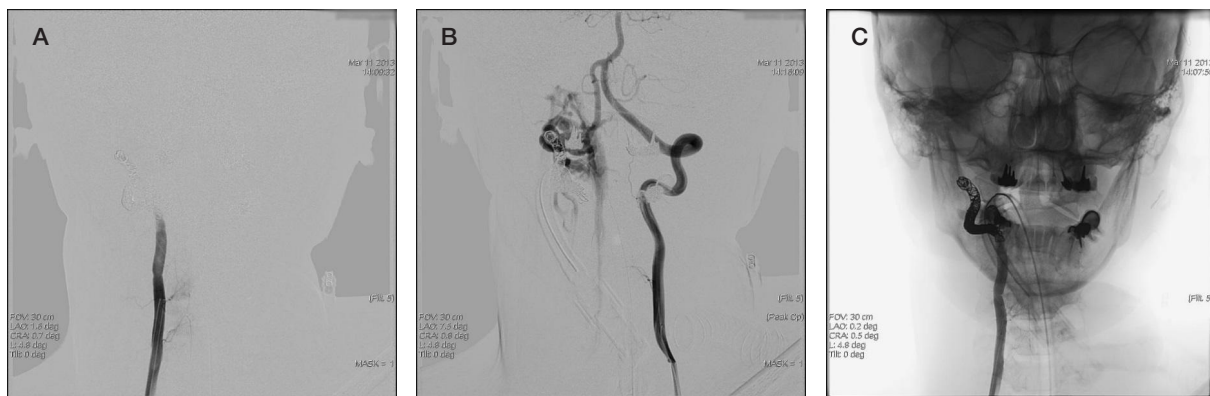


Fig. 5. The intraoperative angiogram, of the right (A, C) and left (B) vertebral arteries, frontal view. Retrograde opacification of the fistula via the left vertebral artery is observed

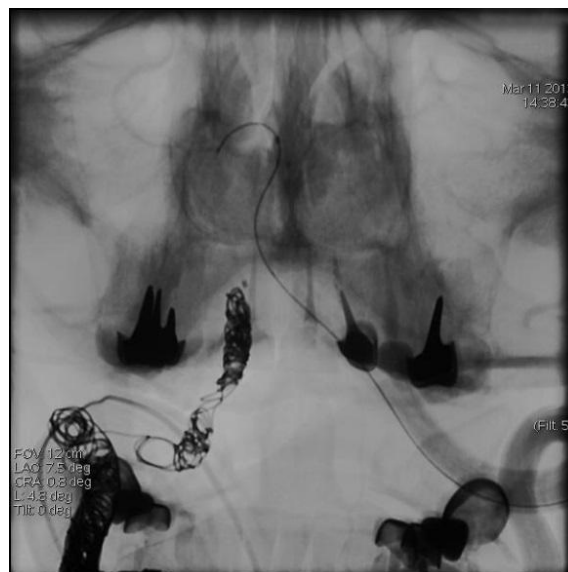

Fig. 6. Occlusion of the distal segment of the right vertebral artery via the collateral approach

prevent migration of coils into the fistula, the embolization was balloon-assisted. The single-lumen Hyperform balloon (Medtronic, USA) was inflated proximal to the tip of the Echelon-10 microcatheter. Then six platinum microcoils were tightly packed inside the right vertebral artery proximal to the fistula. The malformation appeared anterogradely unopacified on the angiogram; but retrograde opacification via the left vertebral artery was still observed. So, the guiding catheter was moved to the lumen of the left vertebral artery (Fig. 5). Similarly, it was passed through the junction of the vertebral arteries to the distal right vertebral artery. Microcoils were

placed immediately between the fistula and the mouth of the right posterior inferior cerebellar artery (Fig. 6). Now the totally embolized fistula appeared unopacified on the angiogram (Fig. 7). The symptoms resolved straight away. The patient was discharged on the day following the surgery.

Clinical case discussion

An arteriovenous fistula is an abnormal connection between the arterial and venous blood vessels that bypasses the capillary network and does not form its own microvasculature.

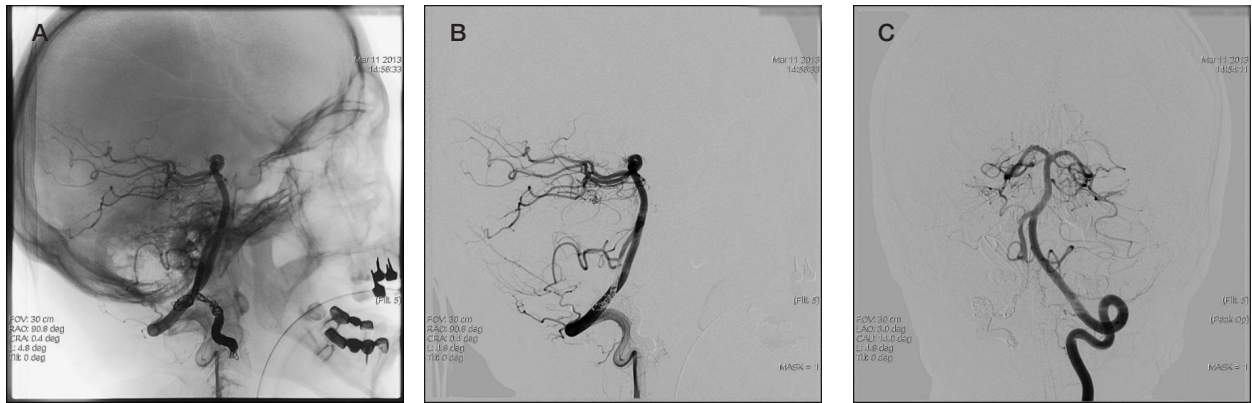


Fig. 7. Native (A) and subtraction (B, C) angiograms of the left vertebral artery appearing in the frontal (C) and lateral (A, B) views. The vertebrobasilar system is totally contrast-opacified while the fistula is not

The majority of arteriovenous fistulas are either acquired or iatrogenic, but congenital ones are also known. Clinical manifestations vary and depend upon the location of the fistula. The most common symptoms are seizures, dizziness, eye movement dysfunction, headaches, and signs of intracranial hypertension [19]. In patients presenting with these symptoms after a surgery that caused an accidental injury to the vertebral artery, the accurate and timely diagnosis depends on the surgeon's vigilance in the postoperative period and their awareness of the possibility of fistula formation [20]. In most cases a timely diagnosed fistula is curable; however, being a rapidly progressing pathology, it needs urgent surgical treatment.

CONCLUSIONS

Delayed formation of the arteriovenous fistula is a rare complication of retrosigmoid craniotomy. The diagnosis is complicated by the lack of specific radiographic signs of the pathology on routinely taken postoperative CT or MR images. The gold standard in the diagnosis of arteriovenous fistulas is cerebral angiography. Endovascular embolization of the fistula is the treatment of choice. Perfect knowledge of skull base anatomy and skills required to stop the bleeding from an accidentally injured artery reduce the risk of fatal complications. Every surgeon should be aware of the possibility of complications and long-term effects of intraoperative damage to the vertebral artery.

References

- Nonaka Y, et al. Contemporary surgical management of vestibular schwannomas: analysis of complications and lessons learned over the past decade. *Neurosurgery*, 2013; 72 (2 Suppl Operative): 103–15; discussion ons115.
- Gal TJ, Shinn J, Huang B. Current epidemiology and management trends in acoustic neuroma. *Otolaryngol Head Neck Surg* 2010; 142 (5): 677–81.
- Pogodzinski MS, Harner SG, Link MJ. Patient choice in treatment of vestibular schwannoma. *Otolaryngol Head Neck Surg* 2004; 130 (5): 611–6.
- Arriaga MA, Lin J. Translabyrinthine approach: indications, techniques, and results. *Otolaryngol Clin North Am*. 2012; 45 (2): 399–415.
- Angeli S. Middle fossa approach: indications, technique, and results. *Otolaryngol Clin North Am*. 2012; 45 (2): 417–38.
- Elhammady MS, Telischi FF, Morcos JJ. Retrosigmoid approach: indications, techniques, and results. *Otolaryngol Clin North Am*. 2012; 45 (2): 375–97.
- Rabelo de Freitas M, et al. Analysis of hearing preservation and facial nerve function for patients undergoing vestibular schwannoma surgery: the middle cranial fossa approach versus the retrosigmoid approach—personal experience and literature review. *Audiol Neurootol*. 2012; 17 (2): 71–81.
- Sughrue ME, et al. Beyond audiofacial morbidity after vestibular schwannoma surgery. *J Neurosurg*. 2011; 114 (2): 367–74.
- Ebersold MJ, et al. Current results of the retrosigmoid approach to acoustic neurinoma. *J Neurosurg*. 1992; 76 (6): 901–9.
- McClelland S, 3rd, Guo H, Okuyemi KS. Morbidity and mortality following acoustic neuroma excision in the United States: analysis of racial disparities during a decade in the radiosurgery era. *Neuro Oncol*. 2011; 13 (11): 1252–9.
- Wiet RJ, et al. Complications in the approach to acoustic tumor surgery. *Ann Otol Rhinol Laryngol*. 1986; 95 (1 Pt 1): 28–31.
- Slattery WH, 3rd, Francis S, House KC. Perioperative morbidity of acoustic neuroma surgery. *Otol Neurotol*. 2001; 22 (6): 895–902.
- Selesnick SH, et al. The incidence of cerebrospinal fluid leak after vestibular schwannoma surgery. *Otol Neurotol*. 2004; 25 (3): 387–93.
- Sade B, Mohr G, Dufour JJ. Vascular complications of vestibular schwannoma surgery: a comparison of the suboccipital retrosigmoid and translabyrinthine approaches. *J Neurosurg*. 2006; 105 (2): 200–4.
- de los Reyes RA, et al. Direct repair of an extracranial vertebral artery pseudoaneurysm: case report and review of the literature. *Neurosurgery*. 1990; 26 (3): 528–33.
- Inamasu J, Guiot BH. Iatrogenic vertebral artery injury. *Acta Neurol Scand*. 2005; 112 (6): 349–57.
- George B, Bresson D, Bruneau M. Pathology and surgery around the vertebral artery. Springer-Verlag. Paris: 2011.
- Schroeder GD, Hsu WK. Vertebral artery injuries in cervical spine surgery. *Surg Neurol Int*. 2013; 4 (Suppl 5): 362–7.
- Li PM, et al. Dural arteriovenous fistula following translabyrinthine resection of cerebellopontine angle tumors: report of two cases. *Skull Base Rep*. 2011; 1 (1): 51–8.
- Cohen SD, et al. Dural arteriovenous fistula: diagnosis, treatment, and outcomes. *Laryngoscope*. 2009; 119 (2): 293–7.

Литература

- Nonaka Y, et al. Contemporary surgical management of vestibular schwannomas: analysis of complications and lessons learned over the past decade. *Neurosurgery*, 2013; 72 (2 Suppl Operative): 103–15; discussion ons115.

2. Gal TJ, Shinn J, Huang B. Current epidemiology and management trends in acoustic neuroma. *Otolaryngol Head Neck Surg* 2010; 142 (5): 677–81.
3. Pogodzinski MS, Harner SG, Link MJ. Patient choice in treatment of vestibular schwannoma. *Otolaryngol Head Neck Surg* 2004; 130 (5): 611–6.
4. Ariaga MA, Lin J. Translabyrinthine approach: indications, techniques, and results. *Otolaryngol Clin North Am.* 2012; 45 (2): 399–415.
5. Angeli S. Middle fossa approach: indications, technique, and results. *Otolaryngol Clin North Am.* 2012; 45 (2): 417–38.
6. Elhammady MS, Telischi FF, Morcos JJ. Retrosigmoid approach: indications, techniques, and results. *Otolaryngol Clin North Am.* 2012; 45 (2): 375–97.
7. Rabelo de Freitas M, et al. Analysis of hearing preservation and facial nerve function for patients undergoing vestibular schwannoma surgery: the middle cranial fossa approach versus the retrosigmoid approach—personal experience and literature review. *Audiol Neurootol.* 2012; 17 (2): 71–81.
8. Sughrue ME, et al. Beyond audiofacial morbidity after vestibular schwannoma surgery. *J Neurosurg.* 2011; 114 (2): 367–74.
9. Ebersold MJ, et al. Current results of the retrosigmoid approach to acoustic neurinoma. *J Neurosurg.* 1992; 76 (6): 901–9.
10. McClelland S, 3rd, Guo H, Okuyemi KS. Morbidity and mortality following acoustic neuroma excision in the United States: analysis of racial disparities during a decade in the radiosurgery era. *Neuro Oncol.* 2011; 13 (11): 1252–9.
11. Wiet RJ, et al. Complications in the approach to acoustic tumor surgery. *Ann Otol Rhinol Laryngol.* 1986; 95 (1 Pt 1): 28–31.
12. Slattery WH, 3rd, Francis S, House KC. Perioperative morbidity of acoustic neuroma surgery. *Otol Neurotol.* 2001; 22 (6): 895–902.
13. Selesnick SH, et al. The incidence of cerebrospinal fluid leak after vestibular schwannoma surgery. *Otol Neurotol.* 2004; 25 (3): 387–93.
14. Sade B, Mohr G, Dufour JJ. Vascular complications of vestibular schwannoma surgery: a comparison of the suboccipital retrosigmoid and translabyrinthine approaches. *J Neurosurg.* 2006; 105 (2): 200–4.
15. de los Reyes RA, et al. Direct repair of an extracranial vertebral artery pseudoaneurysm: case report and review of the literature. *Neurosurgery.* 1990; 26 (3): 528–33.
16. Inamasu J, Guiot BH. Iatrogenic vertebral artery injury. *Acta Neurol Scand.* 2005; 112 (6): 349–57.
17. George B, Bresson D, Bruneau M. Pathology and surgery around the vertebral artery. Springer-Verlag. Paris: 2011.
18. Schroeder GD, Hsu WK. Vertebral artery injuries in cervical spine surgery. *Surg Neurol Int.* 2013; 4 (Suppl 5): 362–7.
19. Li PM, et al. Dural arteriovenous fistula following translabyrinthine resection of cerebellopontine angle tumors: report of two cases. *Skull Base Rep.* 2011; 1 (1): 51–8.
20. Cohen SD, et al. Dural arteriovenous fistula: diagnosis, treatment, and outcomes. *Laryngoscope.* 2009; 119 (2): 293–7.